

## **Parasitic Fauna of Camel in Pakistan**

A. H. Anwar and M. N. Khan

Department of Veterinary Parasitology, University of Agriculture, Faisalabad, 38040, Pakistan

### **ABSTRACT**

This paper reviews the results of the studies conducted on parasitism of camels in the Department of Veterinary Parasitology, University of Agriculture, Faisalabad, Pakistan. Hydatid cysts were recovered from 77.5% (465/600) of camels slaughtered at Faisalabad abattoir. The prevalence was higher (69.2%) in males than in females (30.8%). The organ distribution of cysts was 77.4% in lungs, 19.4% in both liver and lungs; and 3.2% in liver only. The range of number of cysts was 2-275 and 3-115 on lungs and livers respectively. The prevalence of gastrointestinal helminthes was 69.1% (415/600) and that of protozoa was 12.5% (75/600). Of these 32.5% (135/315) had mixed infection of helminthes.

The worm burden per animal ranged from 20-330, 4-40 and 30-250 for trematodes, cestodes and nematodes, respectively. The overall prevalence of ectoparasites was 57% (285/500) including 13.4, 38.8, 3.2 and 1.6% of mites, ticks, lice and mixed infestation (mites and ticks), respectively.

**Key words:** Parasites, Camel, Pakistan.

### **INTRODUCTION**

Despite mechanical advances in the means of transportation, the camel is still an important animal used for carriage purposes in addition to being a good source of milk and meat. The existing population of camels in Pakistan is more than one million and constitutes about 5.1% of the 17.44 million global population, which is increasing at the rate of 1.62% per year.

Parasitism is one of the major problems that affects the productivity and performance of camels (Mohamed, 1994). Parasitic diseases either lower the working efficiency or even may result in death of the animals or sometimes are potential danger for public

health like hydatidosis. The gastrointestinal helminth parasites adversely affect the nutritional status of the animals (Irfan, 1984), whereas the ectoparasites harm the camel due to their parasitic nature and serve as a vector for transmission of a wide variety of pathogens (Pegram and Higgins, 1991). The studies reviewed in this paper are, therefore, of great significance to assess the parasitic fauna of camels in Pakistan.

## **MATERIALS AND METHODS**

The studies being reported were conducted in the Department of Veterinary Parasitology, University of Agriculture, Faisalabad. The samples of liver/lungs and guts were brought from the local abattoir where camels are often brought for slaughtering from the adjoining areas of Punjab.

### **Hydatidosis**

Six hundred camels were examined for the presence of hydatid disease (Anwar, 1987). The lungs and liver of each animal were examined grossly for the presence of hydatid cysts. Organ specificity, size, sex and number of cysts on each organ were also studied.

### **Gastrointestinal parasites**

Six hundred guts were collected and incised longitudinally (Hussain, 1994). The contents of the gastrointestinal contents were examined by sedimentation or sieving method (Morgan and Hawkins 1960). The adult worms were picked up with forceps and washed two or three times in distilled water and preserved in 10% formalin. The fecal samples from the guts were also examined by direct method and flotation technique (Levine, 1973). Fecal samples positive for coccidia were cultured in 2.5% Potassium dichromate solution at room temperature and the sporulated oocysts of coccidia were identified.

## Ectoparasites

A total of 500 camels were examined for the presence of ectoparasites (Mohamed, 1994). Mites were collected (Higgins, 1984) and identified by making permanent mounts (Noble and Noble, 1976; Soulsby, 1982). The ticks and lice were collected and identified according to the methods described by Soulsby, (1982).

## RESULTS

Results have been depicted in Fig. 1. Hydatid cysts were recovered from 77.5% (465/600) of camels slaughtered at Faisalabad abattoir. The prevalence was higher (69.2%) in males than in females (30.8%). The organ distribution of cysts in infected animals was 77.4% in lungs (Fig. 2), 19.4% in both liver and lungs; and 3.2% in liver (Fig. 3) only. The cyst on lungs had an average of 7.8 cm (range 0.4-15.2 cm); and those on liver had an average size of 4.5 cm (range 0.5-8.5 cm). The number of cysts ranged from 2-275 and 3-115 on lungs and livers, respectively.

The prevalence of gastrointestinal helminths was 69.1% (415/600) and that of protozoa was 12.5% (75/600). Of these 32.5% (135/415) had mixed infection of helminths (more than one species of parasites). The species of helminths recovered were: *Paramphistomum cervi* (1.6%), *Carmyerius spatiosus* (1.1%), *Gastrothylax crumenifer* (1.5%), *Moniezia expansa* (9.1%), *Moniezia benedeni* (7.8%), *Stilesia globipunctata* (5.5%), *Haemonchus contortus* (5.0%), *Haemonchus longistipes* (7.1%), *Trichuris globulosa* (4.1%), *Trichuris ovis* (7.0%), *Trichostrongylus probollurus* (4.1%), *Camelostrongylus mentulatus* (3.3%), *Oesophagostomum venulosum* (2.5%), *Cooperia onchophora* (2.5%), *Ostertagia circumcincta* (3.3%) and *Chabertia ovina* (3.1%).

The worm burden per animal ranged from 20-330, 4-40 and 30-250 for trematodes, cestodes and nematodes, respectively. The species of protozoa recorded were *Eimeria cameli*, *Globidium cameli*, *Eimeria dromedarii* and *Trypanosoma evansi* in blood smear. The overall prevalence of ectoparasites was 57% (285/500) including 13.4, 38.8, 3.2 and 1.6% of mites, ticks, and lice and mixed infestation (mites and ticks), respectively. The species of ectoparasites recorded were *Sarcoptes scabiei* var. *cameli*,

*Hyalomma (H) dromedarii*, *H. anatolicum anatolicum*, *H. aegyptium* and *Haemotopinus cameli*.

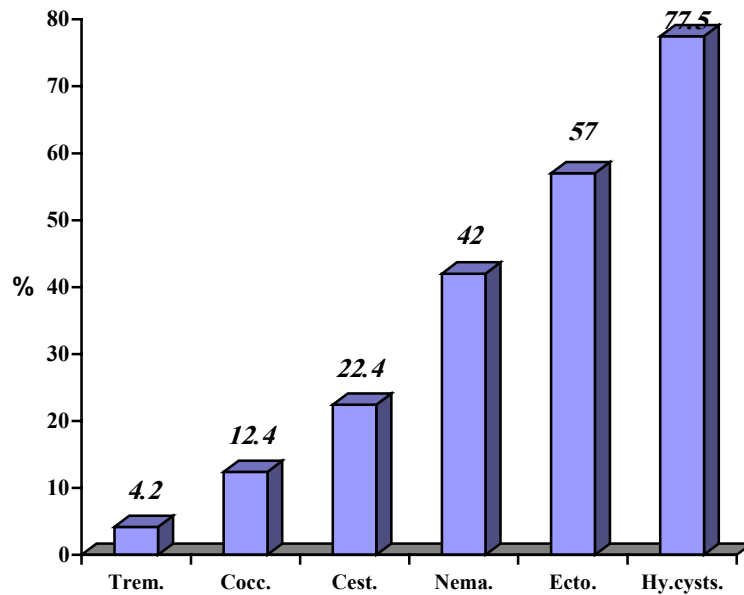


Fig. 1: Prevalence (%) of different parasitic problems of camels in Pakistan

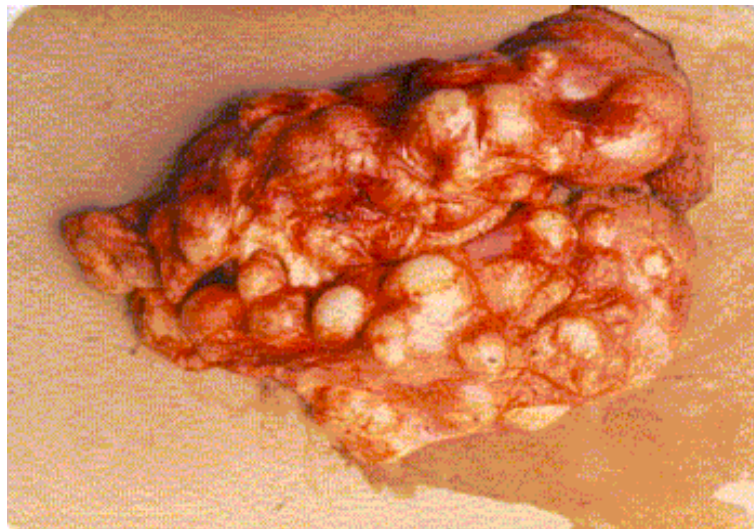


Fig. 2: Polycystic stage of hydatid cyst in lung

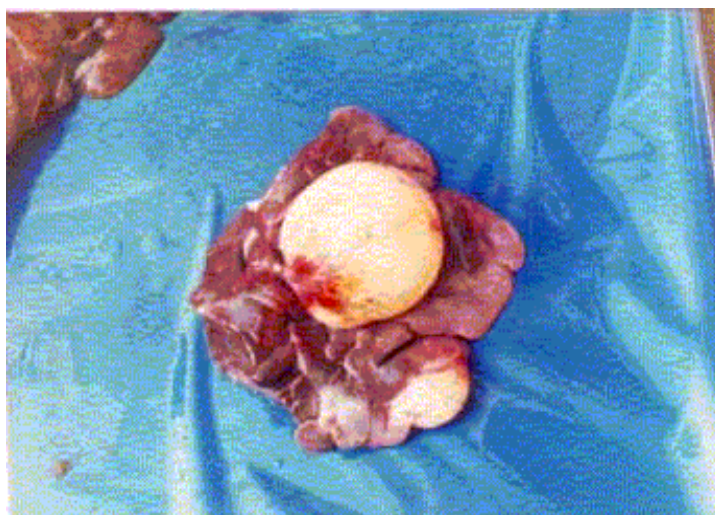


Fig. 3: Hydatid cyst in liver

## DISCUSSION

It is evident from the results of these studies that the camel is a hard hit victim of different types of parasites in Pakistan. The high prevalence hydatid cysts in camels indicate a well-perpetuated life cycle of *Echinococcus granulosus* in Pakistan. This is not only a threat to the health of camels but also is a potential danger for the human population particularly those inhabiting rural areas where diagnostic facilities are rarely available. Likewise, occurrence of a large variety of gastrointestinal worms/protozoa is taking a high toll on the camels, adversely affecting their health and vitality. Similarly, the ectoparasites not only directly harm camels but also transmit diseases of high economic significance e.g. trypanosomiasis, babesiosis, etc. which has also been reported from Pakistan. Those of Khan, (1991) who isolated protozoal, substantiate these findings as well as bacterial pathogens from ticks infesting cattle and buffaloes.

Parasitic diseases recorded in these studies have been frequently reported; hydatidosis (Rausch, 1967; Dent and Kelly, 1976; Afshar *et al.*, 1971; Sedik and Salam, 1978); gastrointestinal parasites (El-Bihari, 1984; Kasim *et al.*, 1985; Anwar, 1987); and ectoparasites (Wilson, 1984; Grigoryan, 1987; Njanja, 1991).

It is concluded from the results of these studies that parasitism is one of the major health problems of camels which needs

special attention to save the already poor people from poverty who are the main camel keepers in Pakistan. These people use camels for carriage purposes as well as a source of milk and meat in addition to their use as draught animals. For this purpose, it is suggested that camel centres be established in the country to look after the health, management and breeding aspects of the camels.

## REFERENCES

- Afshar, A. A., I. Nazarian and B. Baghban-Baseer. 1971. A survey of the incidence of hydatid cyst in camels in south Iran. *British Vet. J.* 127:554.
- Anwar, M. 1987. A study on the prevalence of gastrointestinal parasites of one-humped camel (*Camelus dromedarius*). M.Sc. Thesis, Department of Veterinary Parasitology, University of Agriculture, Faisalabad.
- Dent, C. H. R. and J. D. Kelly. 1976. Cestodes parasites of dog in central table land of New South Wales. *Aust. Vet. J.* 52: 386-388.
- El-Bihari, S. 1984. Helminths of the camels. A review. *British Vet. J.* 141: 315-326.
- Grigoryan, V. V. 1987. Sarcoptic mange in camel. *Vet. Moscow*, 12: 49-50.
- Higgins, A. J. 1984. Diagnosis and treatment of sarcoptic mange in the Arabian camel. *World Animal Review.* 49: 2-5.
- Hussain, I. 1994. Prevalence of gastrointestinal helminthes in the dromedary camel and efficacy of injectable ivermectin against them. M. Sc. Thesis. Department of Veterinary Parasitology, University of Agriculture, Faisalabad.
- Irfan, M. 1984. Keynote address on affects of parasitism on livestock production. *Pakistan Vet. J.* 4: 25-27.

- Kasim, A. A., H. S. Hussain and Y. R. Al-Shawa. 1985. Coccidia in camels (*Camelus dromedarius*) in Saudi Arabia. J. Protozoal. 32: 202-203.
- Khan, M. N. 1991. Studies on the prevalence, vector role and control on ticks on livestock. Ph.D. Thesis, Department of Veterinary Parasitology, University of Agriculture, Faisalabad.
- Levine, N. D. 1973. Protozoan parasites of domestic animals and of man. Burgess Publishing Company, Minneapolis, Minnesota. U.S.A.
- Mohamed, 1994. Studies on the prevalence and chemotherapy of ectoparasites of the dromedary camel in and around Faisalabad. M. Sc. Thesis, Department of Veterinary Parasitology, University of Agriculture, Faisalabad.
- Morgan, B. and P. A. Hawkins. 1960. Veterinary helminthology. 5<sup>th</sup> ed., Burgess Publishing Company, U.S.A.
- Njanja, J. C. 1991. Therapeutic use of ivermectin against sarcoptic mange in camels. Bull. Anim. Hlth. Prod. Africa, 39: 275-279.
- Noble, R. and A. Noble. 1976. The biology of animal parasites. Lea and Febiger, Philadelphia, U.S.A.
- Pegram, R. G. and A. J. Higgins. 1991. A review of camel ectoparasites. Proc. 1<sup>st</sup> Intl. Camel Conf. UAE, P. 69-78.
- Rausch, R. 1967. On the ecology and distribution of *Echinococcus spp.* and characteristics of their development in the intermediate host. Ann. Parasitol. 1: 19-63.
- Sedik, M. E. and M. A. Salam. 1978. Incidence of Echinococcus among slaughtered animals at Cairo abattoir. Assiut Vet. Med. J. 4: 171.
- Soulsby, E. J. L. 1982. Helminthes, arthropods and protozoa of domesticated animals. 7<sup>th</sup> ed., Bailliere Tindall and Company, London.

Wilson, R. J. 1984. The camel. 1<sup>st</sup> ed., Longman Group Ltd.,  
Longman House Mill, Harlow Essex, U.K.