

Epizootiology of Camel Pox, Camel Contagious Ecthyma and Camel Papillomatosis in the Sudan

A. I. Khalafalla

Department of Microbiology, Faculty of Veterinary Science,
University of Khartoum. P. O. Box 32, North Khatoum, Sudan

ABSTRACT

An extensive field survey of camels in eastern Sudan for the occurrence of camel pox, camel contagious ecthyma (CCE) and camel papillomatosis was carried out between 1992 and 1994. These three diseases are a group of exanthematous skin conditions, which recently emerged as being of increasing economic significance. Thirty-five outbreaks of camel pox were reported. The disease occurred in epizootics that lasted for 2-5 months with higher prevalence in the winter months of the year. Morbidity and mortality rates were 9% and 1.2%, respectively, while the case fatality rate was 14%. Most of the affected animals were young, less than five years old, and all deaths occurred in young animals' aged less than three years.

The disease spread mainly by direct contact with sick animals particularly at watering places. Lymph node enlargement and appearance of localized or generalized pox lesions characterized clinical signs. The course of camel pox ranged between 15 to 30 days and occasionally extended for up to 4 months. Antibodies against camel pox, as detected by ELISA, indicated that the disease was already wide spread in all parts of the Sudan where camels are raised. Camel contagious ecthyma, on the other hand, was found to be endemic in eastern Sudan. Thirty-eight herds of camels were affected with the disease. Clinically, the pox lesions were characterized by the appearance of scabs and fissured crusts. All cases occurred in young animals up to three years old. The mean morbidity and mortality rates in calves' less than one year old was 60.2% and 8.8%, respectively, while the mean case fatality rate was 14.5%. The disease has been marked as seasonal, being associated with the rainy months of the year.

Papillomatosis (warts) was also reported during this study in camels from different areas of Sudan. The disease appears as round, cauliflower-like horny masses mainly found on the skin of the lips and submandibular area. The disease occurred in young camels of less than two years.

Key words: Camel pox, Camel contagious eczema, Camel Papillomatosis, Sudan.

INTRODUCTION

Sudan is the second most densely populated country in the world by camels, following Somalia. The recent estimate of the number of this species in Sudan was 3.1 million (Schwartz and Dioli, 1992). Dromedaries in Sudan are distributed in the arid and semi-arid parts of the country, which lie north of 13°N latitude where the annual rainfall is less than 350 mm. However, because of the droughts of the northern parts of the country, camels are moved south of this line.

In the literature there is only a little information on camel diseases compared to other species of animals. This may be due mainly to the fact that camel production is usually practiced on a migratory system in remote areas with harsh living conditions that make such studies difficult and expensive to execute.

Camels are susceptible to many infectious diseases, some of which have been investigated extensively because they also affect other species of farm animals. Such diseases include trypanosomiasis, anthrax, hemorrhagic septicemia, brucellosis, mange and pox (McGrane and Higgins, 1984). Pox and pox-like diseases of camels are a group of exanthematous skin conditions which recently emerged as being of increasing economic importance (Munz, 1992). They may be caused by three distinct viruses: *Orthopoxvirus cameli* (camel pox), *Parapoxvirus* (camel contagious eczema) and *Papilloma virus* (camel papilloma virus infection) (Munz, 1992).

Camel pox is a highly contagious viral disease affecting mostly young animals and is characterized by papular pustular eruptions on the skin and mucous membranes. During the past ten years, reports have appeared on outbreaks of camel pox from Egypt, Iraq, Iran, India, Yemen, Bahrain, Saudi Arabia, Nigeria, Ethiopia, Kenya,

Morocco, Somalia and the former USSR. Camel pox, which was known to exist for years in Sudan under the name Al Geddari, was first reported in 1953. However, the identification of its causative agent has not been made (Shommein and Osman, 1987).

Camel contagious ecthyma was first described in Kazakhstan in 1968 (Buchnev *et al.*, 1987). There are few studies on this disease and the description of its causal agent in the literature. Published results, are difficult to compare (Munz *et al.*, 1986). The disease is characterized by localized lesions, although generalized forms have also been observed, resembling true camel pox (Munz, 1992). Camel contagious ecthyma is caused by a parapox virus, which has been identified in camels in the former USSR, Mongolia, Kenya and Somalia. Recently the disease was reported in western and eastern Sudan (Ali *et al.*, 1991; Khalafalla *et al.*, 1994).

Outbreaks of papillomatosis in camels were reported in Somalia by Munz *et al.*, (1990). Infections lead to a wart-like lesion often found around the lips and nostrils and maybe misdiagnosed as a pox disease especially where generalized lesions occur (Munz, 1992). Mixed infections of warts and CCE were sometimes found in the same herd.

According to Munz, (1992), the clinical signs of camel pox in affected animals are often indistinguishable from lesions caused by parapox virus (CCE) or papilloma virus. The available information on pox and pox-like diseases of camels is little and unsystematic. Particularly there is a lack of proper epizootiological investigations elucidating and explaining disease patterns according to the prevalent husbandry systems. The very few published reports on the epizootiology of these diseases are either based on short observation periods, one-time surveys or on estimates.

MATERIALS AND METHODS

The study of the epizootiology of pox and pox-like diseases of camels was carried out mainly in Butana area of eastern Sudan. Areas south and southwest of Kassala City and around Atbara River, as well as some areas in the Blue Nile, Kordofan and Darfur, were also included in the survey (Fig. 1).

A continuous survey in which 15 camel herds were visited monthly or bi-monthly between March 1992 to June 1993 was carried out in collaboration with the French-Sudanese Camel

Research Project which aimed at the study of the husbandry and production parameters of camels in Butana area (Agab, 1993). In each visit to Butana area, an additional 15 to 20 herds which were not covered by the above mentioned project were also investigated. Frequent visits were made to the study area between July 1993 and December 1994. During the period of the study, the areas were visited eight times in response to reports of outbreaks of pox or pox-like diseases. Camel herds were investigated for the occurrence of camel pox, CCE and camel papillomatosis. Sick animals were carefully examined for clinical signs, number and location of skin lesions and also for the general body condition. Additional data concerning age and sex of animals affected or dead were collected. Herders' accounts of disease history and the progress of signs were also recorded.

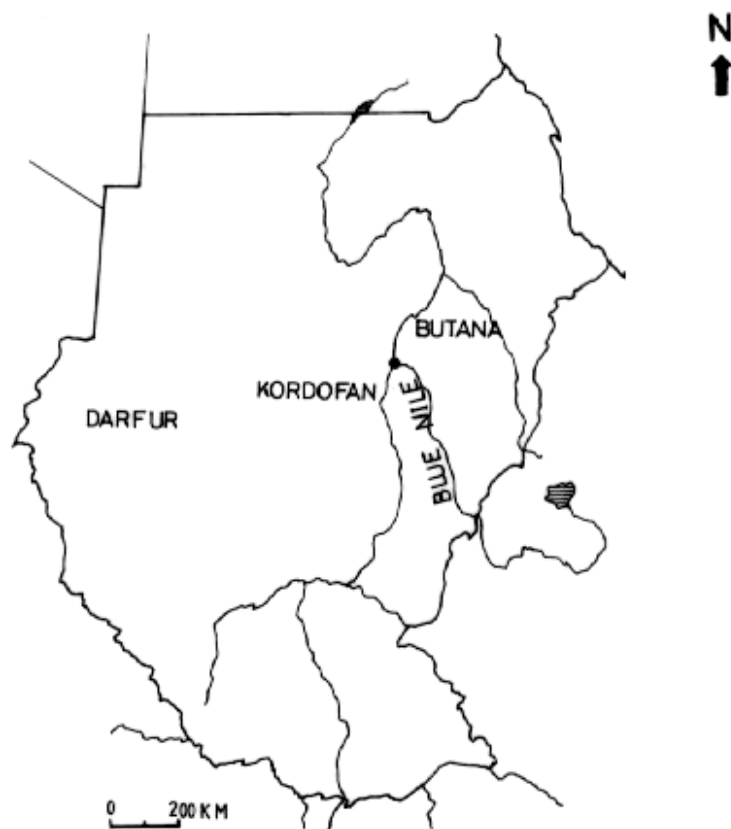

Fig. 1: Map of Sudan showing the study area

Identification of the causative agents of camel pox and CCE was achieved through direct examination of skin samples by negative contrast electron microscopy and/or virus isolation and identification. Cases of Papillomasis were diagnosed mainly by histopathology. In order to determine the prevalence of camel pox in other areas of Sudan, serological survey using ELISA technique was performed on sera collected from camels in Kordofan, Darfur and Blue Nile, in addition to sera collected from Butana area.

RESULTS AND DISCUSSION

Camel pox

The presence of camel pox in Sudan was first reported in 1953. The disease has probably always existed in the country though it had not come to veterinary attention. The clinical signs of camel pox observed in this study varied from acute to mild infection. Acutely affected animals were off food and had fever (morning temperature: 39-40.5 °C), edema of face, lachrymation, lymph node enlargement, papules formation and pendulous lips. Papules and vesicles were first observed on the lips and nostrils and later involved the whole head, neck, buttock, abdomen, legs and groin (Fig. 2). Within 2-5 days of infection papules developed into pustules which dried up into thick scabs within 7-10 days and fell off after 10-15 days. The course of the disease was found to range between 15 and 30 days. Occasionally the course extended for 2 to 4 months with localized pox lesions.

Thirty-five outbreaks of camel pox were reported between March 1992 and December 1994. They occurred in three main epizootics that lasted for two to five months (Table 1). The age distribution of 230 cases of camel pox is shown in Fig. 3. Fifty-four cases of camel pox (23.5%) were recorded in camels up to one year of age, 80 cases (34.5%) were in camels aged between one and two years and 46 cases (20%) were in camels aged between 2 and 3 years. The remaining 50 cases (21%) were recorded in camels above 3 years old. The arithmetic mean age of affected animals was 2.7 years. The morbidity rate of camel pox in a total of 2,560 animals in disease outbreaks involving 35 herds was found to be 9%. Thirty-two of the affected animals died in giving an overall mortality rate of 1.2% and a case fatality rate of 14%.



Fig. 2: Camel pox: A three year-old female camel showing pox eruptions on the groin and inner thighs.

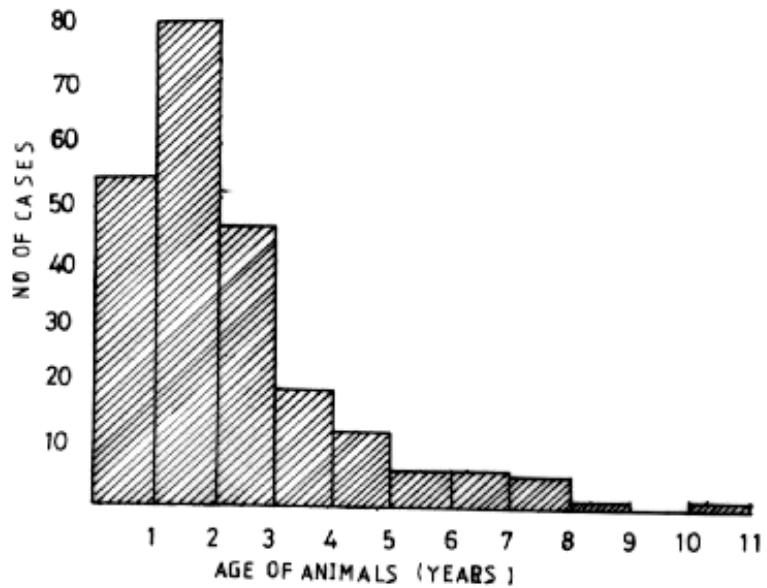


Fig. 3: Epizootiology of camel pox: Age distribution of cases.

Table 1: Pattern of camel pox outbreaks in eastern Sudan (1992-1994).

Epizootic No.	Period of Time	No. of Outbreaks	Location of Outbreaks
1	March-May, 1992	6	River Atbara & Southern Butana
2	August-November, 1992	9	Central Butana & Kassala area
3	November 1993-April, 1994	20	Central Butana & River Atbara

The age distribution of mortality indicated that deaths occurred in 10 animals in the age group zero to one year (31.3%), in comparison to 20 animals in the age group 1-2 years (62.5%) and two animals (6.2%) in the age group 2-3 years. None of the affected animals above 3 years of age died. The results of the present study have shown that camel pox in eastern Sudan caused morbidity and mortality rates of 9.1% and 1.2%, respectively. Kriz, (1982) gave morbidity and mortality rates due to camel pox in Somalia of 28% and 5.4%, respectively. According to Munz (1992) morbidity due to Camel Pox might reach 100% depending on the age structure, immunological and nutritional status of the herd, stress, inter-current diseases and virulence of the virus strain involved.

According to the present study, camel pox seems to occur in epizootic forms appearing from time to time depending on the availability of susceptible animals. This agreed with Borisovich and Orekhov, (1966) who observed that camel pox in Turkemia flared up every 3-5 years while Pfahler *et al.*, (1989) reported that camel pox outbreaks occur every 2-3 years.

Most of camels affected with camel pox during this study were young immature animals up to three years old. It seemed that camels born during the inter-epizootic period and those previously exposed

to the virus after waning of the immunity became the target and the susceptible group for the next epizootic of the disease.

Transmission of camel pox virus is believed to occur horizontally through direct or indirect contact (Higgins, 1983; Munz, 1992). In most of camel pox outbreaks investigated in the present study, the disease occurred as a result of direct contact between sick and susceptible animals and the infection spread faster when animals were gathered, commonly at watering and grazing points. Contamination of drinking water by virus, laden saliva and dry scabs might have played an important role in the spread of camel pox in the study area. The source of infection could also be through the introduction of newly purchased animals to the herd. In all the three epizootics of camel pox reported in this study, the spread of the disease was found to follow the direction of camel movements. In eastern Sudan, camels have a regular migratory pattern and are generally moved southward during the dry season and northward during the rainy season (Agab, 1993). The movements of camels with a regular migratory pattern seemed to contribute more towards the dissemination of camel pox virus.

No human infections attributed to camel pox were seen in the study area during the time of this study, and no other species of animals other than camels were found to be affected. These findings supported the conclusion that camel pox is of no epidemiological importance to man (Kriz, 1982; Wernery and Kaaden, 1995).

Antibodies against camel pox as detected by ELISA indicated that the disease was always widespread in all parts of Sudan where camels are raised. The highest level of camel pox antibodies was detected in camels from Darfur (western Sudan) followed by Kordofan (western Sudan) and then Blue Nile area and the lowest incidence was in camels from Butana area of eastern Sudan (Table 2). It could be postulated that a significant epizootic of camel pox had occurred in Darfur area during the period preceding our sample collection in December 1994. The findings of the present study revealed that the percentage of sero-positive animals increased with age, which further supports the fact that young camels are the most susceptible age group.

Table 2: Prevalence of camel pox antibodies in sera of some camels in Sudan.

Area	No. of Animals Tested	No. of Sero-positive Animals ¹	Percentage of positive
Butana	224	124	55%
Blue Nile	101	78	77%
Kordofan	77	67	87%
Darfur	103	97	94%
Total	505	366	73%

¹Antibody titres of 1/128 or more in ELISA

Recent attempts at producing a vaccine against camel pox have come from Morocco, Saudi Arabia and U.A.E. (Kaaden *et al.*, 1992; Wernery and Kaaden, 1995). The three countries succeeded in producing cell culture attenuated camel pox vaccines from their local isolates. Accordingly, on the basis of information in this study, we strongly recommend setting up a project for camel pox vaccine production in Sudan.

Camel contagious ecthyma:

Clinically, nodules appeared on the lips of affected animals followed in most cases with swelling of the face and sometimes the neck (Fig. 4). Papules and vesicles appeared later and within a few days developed into thick scabs and fissured crusts (Fig. 5). Lesions occurred sometimes on the face, eyes and nares and, in severe cases, on the gingival, dental pad and the tongue. Death was probably due to starvation caused by the inability of affected animals to graze or to suckle their dams. Healing occurred within 20 to 30 days in most cases but sometimes the course of the disease extended up to 3 months.



Fig. 4: Camel contagious ecthyma: Acutely affected young camel showing swelling of the head and upper part of the neck.

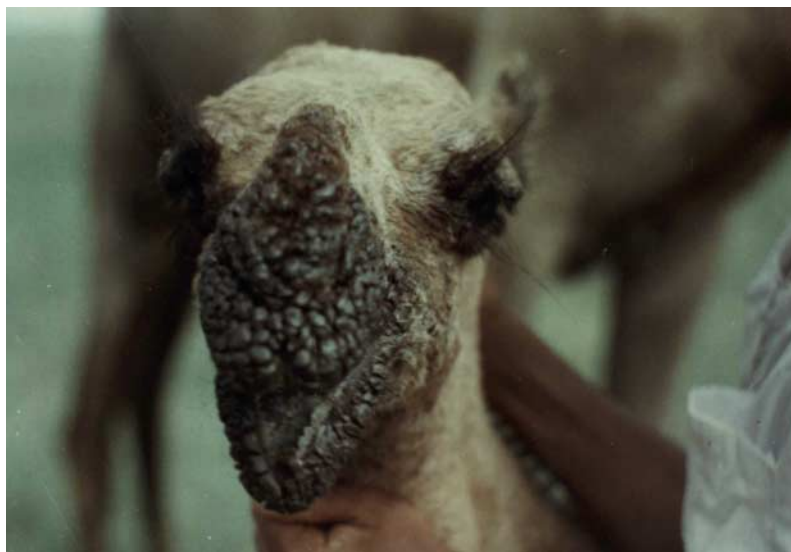


Fig. 5: Camel contagious ecthyma: A close-up view of face affected camel showing scabby lesions around the lips, nostrils and eyes. Note, the lower lip is pendulous.

Out of 305 camel herds surveyed for the occurrence of CCE during the period from March 1992 to June 1993, thirty-eight herds were found to be affected with the disease. The disease was observed in 35 of these herds (92.1%) during the rainy season (July-October) and only three affected herds (7.9%) were recorded in the winter season (November-March), while no disease outbreak was seen in the summer season (April-June) in all the surveyed herds. All cases occurred in young animals up to three years old. Most of the affected animals (62.8%) that were in the age group 7-12 months and 24.1% cases occurred in animals aged 0-6 months (Table 3). The case fatality rate was higher in the age group 0-6 months (24%) than that in the age group 7-12 months (10%).

Table 3: Age distribution of cases and deaths due to camel contagious ecthyma in eastern Sudan.

Age	Cases		No. of Deaths	Fatality rate (%)
	No.	%		
0 – 6 months	66	24	16	24.2
7 – 12 months	172	62	18	10.5
1 – 2 years	4	2	0	0
2 – 3 years	2	1	0	0
Unknown	30	11	6	20
Total	274	100	40	15

Our results show that camel contagious ecthyma is endemic in both Butana area of eastern Sudan and the Blue Nile area. The mean morbidity and mortality rates in camel calves of less than one year old were 60.2% and 8.8%, respectively. The disease had a marked seasonality, being associated with the rainy season, and seemed to occur at this particular time every year and caused high losses in camel calves, especially in the Blue Nile and southern Butana areas.

These findings substantiate the previous reports on the seasonality of CCE and its association with the rainy season (Buchnev *et al.*, 1987; Moallin and Zessin, 1988; Khalafalla *et al.*, 1994). Factors responsible for this epizootiological feature seem to be the abrasion of the skin of the lips, resulting from eating thorny acacia trees at this time of the year when no other source of food was available. The same opinion was also offered by Buchnev *et al.*, (1987) who argued that the thorny plants damaged the lips allowing transmission of parapox virus. Another factor suggested here is the role-played by the movements of camels. We observed that epizootics of the disease in eastern Sudan had followed a south-north direction, which coincided with the movement of camel herds. The disease tended to appear first at the beginning of the rainy season (June) in Blue Nile and southern Butana areas and the infection extended northward coinciding with the annual movement of camels towards Butana plains.

The possible involvement of insect transmission cannot be excluded. The disease seems to have a seasonal prevalence of an arthropod-borne disease. It appears in early rainy season and usually disappears with the end of rains. This possibility is not expected since insects have been reported to be responsible for transmission of other members of the family Pox viridae such as lumpy skin disease virus (Woods, 1988), sheep-pox (Kitching and Mellor, 1986), fowl-pox (Tripathy and Cunningham, 1985), swine-pox virus and myxomatosis virus (Tripathy *et al.*, 1981). Much detailed work would be needed to study the influence of these factors.

In the present study the incidence and severity of CCE varied in different geographical localities. The morbidity and mortality rates were relatively high in camels from the Blue Nile area compared to the rates in camels of central and southern Butana, Kassala or River Atbara. Camels in pastures of dry, short grass and few acacia trees, as in areas of central Butana and round Kassala City, are less affected and the infection was mild. On the other hand, in Blue Nile area where acacia tree forests are abundant with more moisture, a high percentage of young camels become infected with CCE. Measures proposed for the control of camel pox can also apply to CCE. Care should be taken to avoid skin abrasions when possible.

Camel papillomatosis

Eight animals out of 246 in five camel herds were found to be affected with papillomatosis giving an estimated morbidity rate of 3.3%. Table 4 gives details on these cases, including location and date of disease observation, age and breed of affected animals as well as relationship with cases of CCE. All of the affected animals were young camels aged less than two years.

The clinical picture of camel papillomatosis that observed in the present study was similar to that described by Dioli and Stimmelmayer (1992) in Kenya. The wart lesions appeared as round, cauliflower-like horny masses of 0.3-1.5 cm in diameter. The lesions first appeared as small flat elevations, rosy in color or hyperemic. Later, and within 1-2 weeks, they developed into round fissured or cauliflower-like horny masses taking the normal color of the skin (Fig. 6).



Fig. 6: Camel papillomatosis: Advanced stage of the wart growth on the upper and lower lips and the submandibular area.

The wart lesions are commonly found on the skin of the lips and submandibular area. Camels naturally browse on thorny trees and the skin of their face is therefore more subject to injuries and abrasions.

The epizootiological feature of camel papillomatosis observed in this study revealed that the disease occurred in most camel raising areas of Sudan and affected different breeds of camels. The disease predominantly affected young animals 3-14 months old with 3.3% morbidity rate and no mortality.

Spread of the disease was probably through direct contact between affected and susceptible animals. However, there seems to be a close relationship with cases of CCE. Most cases of camel papillomatosis were observed in late rainy season coinciding with outbreaks of CCE. In two cases, mixed infection of papillomatosis and CCE were observed and, in 3 cases, papillomatosis occurred a few weeks after infection with CCE (Table 4). Relationship between papillomatosis and camel pox virus infections were also suggest by Dioli and Stimmelmayer (1992) in Kenya.

Notes on differential diagnosis:

On the bases of data derived from this study on the clinical and epizootiological features for each of the three investigated diseases, it is possible to suggest criteria for differentiating between them. The epizootiological differences between camel pox, CCE and camel papillomatosis described in the present study can be used as a clue. Clinically, in case of camel pox the lesions, which may be localized on the head, neck, abdomen or generalized all over the body are usually observed as round and circumscribed papules, vesicles or scabs. The lesions of CCE, on the other hand, are found in most cases to be confined to the head, in particular to the lips, nostrils and eyes without becoming generalized. Their distinctive feature of the appearance of fissured crusts characterizes the lesions. Quite distinct from the lesions of camel pox and CCE, papillomatosis of camels in Sudan appears as round, cauliflower-like horny masses (warts) found mainly on the lips and skin of the submandibular area without impairing the normal behavior of the affected animal.

IMPLICATIONS

The epizootiological investigations carried out in the present study demonstrated that both camel pox and CCE have a considerable economic impact on camel production in Sudan. The effect of this disease was not only due to mortality of camels but also to loss of weight, poor growth rate, decreased milk yield and also the cost of medicines. On the other hand, papillomatosis was found to be a mild disease of camels in Sudan and, by itself, is of little economic significance. At the moment, this disease does not observe priority but has to be kept under observation since it is possible that Sudan may face an outbreak of unusual severity.

REFERENCES

- Agab, H. (1993). Epidemiology of camel diseases in eastern Sudan with emphasis on brucellosis. M. V. Sc. Thesis, University of Khartoum, Sudan.
- Ali, O. A. S. A., S. A. M. Kheir, H. Abu Damir and M. E. S. Barri. 1991. Camel (*Camelus dromedarius*) contagious ecthyma in Sudan. A case report. *Revue Elev. Med. Vet. Pays. Trop.* 44 (2), 143-145.
- Borisovich, Y. F. and M. D. Orekhov. 1966. Camel pox. *Veterinayia* 3, 50. (Abstract: *Veterinary Bulletin*, 36, 794.
- Buchnev, K. N., S. Z. Tulepbaev and A. R. Sansyzbaev. 1987. Infectious diseases of camels in the USSR. *Revue Sci. Tech. Off. Int. Epizoot.* 6 (2), 487-495.
- Dioli, M. and R. Stimmelmayer. 1992. Important camel diseases. In: *The one humped camel in eastern Africa. A pictorial guide to disease, health care and management.* H.J. Schwartz and M. Dioli (Editors), Verlag Joseph Margraf Scientific Books., p. 155-164.
- Higgins, A. J. 1983. Observations on the diseases of the Arabian camel and their control. A review. *Vet. Bull.* 53 (2), 1089-1100.

- Kaaden, O. R., A. Walz, C. P. Cerny and U. Wernery. 1992. Progress in the development of a camel pox vaccine. In: Proceedings of First International Camel Conference, Dubai, U.A.E. 2nd-6th February, 1992. Allan, W.R., Higgins, A.J., Mayhew, I.G., Snow, D.H. and Wade, J .F. (editors). U. K. R & W Publications (Newmarket) Ltd., p. 47-49.
- Khalafalla, A. I., H. Agab B. and Abbas. 1994. An outbreak of contagious ecthyma in camels (*Camelus dromedarius*) in eastern Sudan. Trop. Anim. Hlth. And Prod., 26, 253-254.
- Kitching, R. P. and P. S. Mellor. 1988. Insect transmission of capripox virus. Research in Veterinary Science 40 (2), 255-258.
- Kriz, B. 1982. A study of camel pox in Somalia. J. Comp. Path. 92, 1-8.
- McGrane, J. J. and A. J. Higgins. 1985. Infectious diseases of the camel; viruses, bacteria and fungi. Br. Vet. J. 141, 529-545.
- Moallin, A. S. M. and K. H. Zessin. 1988. Outbreak of camel contagious ecthyma in central Somalia. Trop. Anim. Hlth. Prod. 20, 185-186.
- Munz, E. 1992. Pox and pox-like diseases of camels. In: Proceedings of First International Camel Conference, Dubai, U.A.E. 2nd-6th February, 1992. Allen, W.R., Higgins, A.J., Mayhew, I.G., Snow, D.H. and Wase, J.F. (editors) U.K. R & W Publications (Newmarket) Ltd., pp. 43-46.
- Munz, E., D. Schillinger, M. Reimann and H. Mahnel. 1986. Electron microscopical diagnosis of ecthyma contagious in camels (*Camelus dromedarius*). First report of the disease in Kenya. J. Vet. Med. B. 33, 73-77.
- Munz, E., A. S. M. Moallin, H. Mahnel and M. Reimann. 1990. Camel papillomatosis in Somalia. J. Vet. Med. B 37, 191-196.

- Pfahler, W. H. E., M. Reimann, and E. Mnuz. 1986. A Biotin-avidin amplified enzyme immunoassay for detection and quantification of orthopox virus camel antibodies in dromedaries. *J. Vet. Med. B* 33, 477-484.
- Schwartz, H. J. and M. Dioli. 1992. The one-humped camel in eastern Africa. A pictorial guide to diseases, health care and management. Verlag, Josef Margraf Scientific Books.
- Shommein, A. M. and A. M. Osman. 1987. Diseases of camels in Sudan. *Rev. Sci. Tech. Off. Int. Epiz.* 6, 481-484.
- Tripathy, D. W. and C. H. Cunningham. 1980. Avian pox. In: Diseases of poultry. Edited by M.S. Hofstad, H.J. Barnes, B.W. Calneck, W.M. Reid and H.W. Yoder, Jr. Iowa State University Press, Ames, Iowa, USA pp. 525-534.
- Tripathy, D. W., L. E. Hanson and R. A. Crandell. 1981. Pox viruses of veterinary importance. In: Comparative diagnosis of virus diseases. Ed. E. Kurstard and C. Kurstard. Academic Press, London, Vol. 3, 267-346. Cited by Tripathy, D.W. and Cunningham, C. H. (1980).
- Wernery, U. and O. R. Kaaden. 1995. Infectious disease of camelids. Blackwell Wissenschafts-verlag, Berlin.
- Woods, J. A. 1988. Lumpy skin disease. A review. *Trop. Anim. Hlth. Prod.* 20, 11-17.